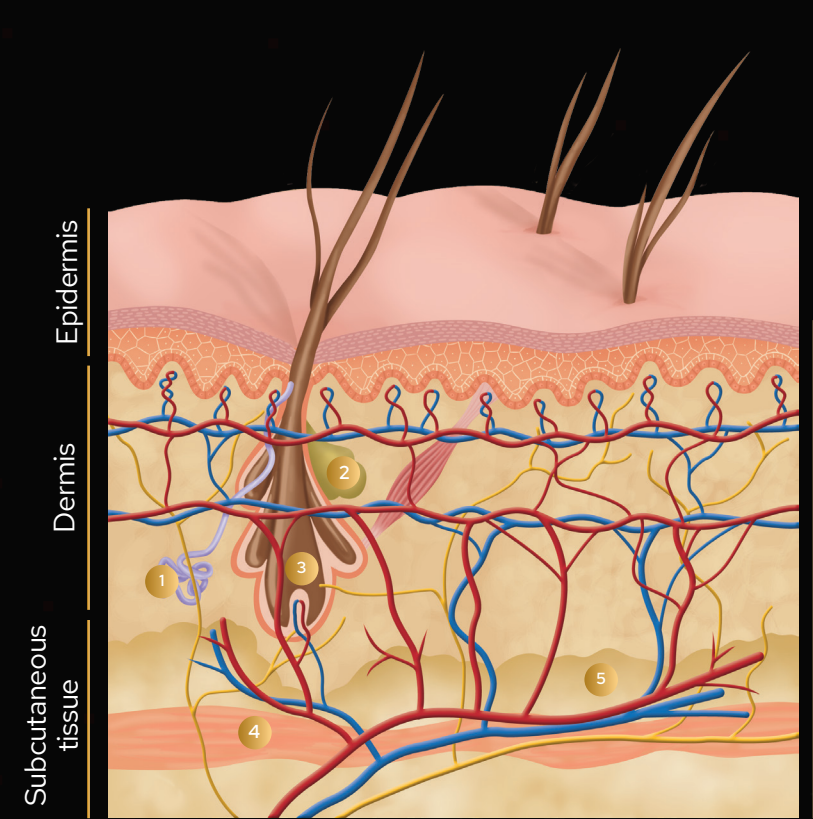


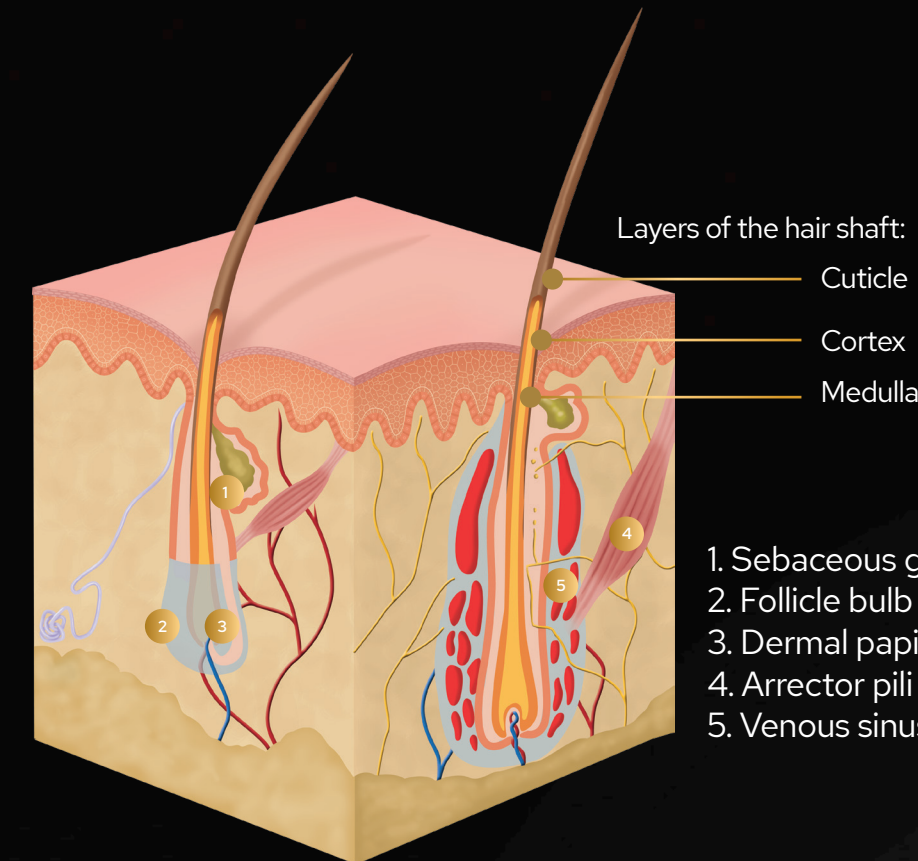
HEALTHY SKIN STRUCTURES

HEALTHY SKIN SECTION



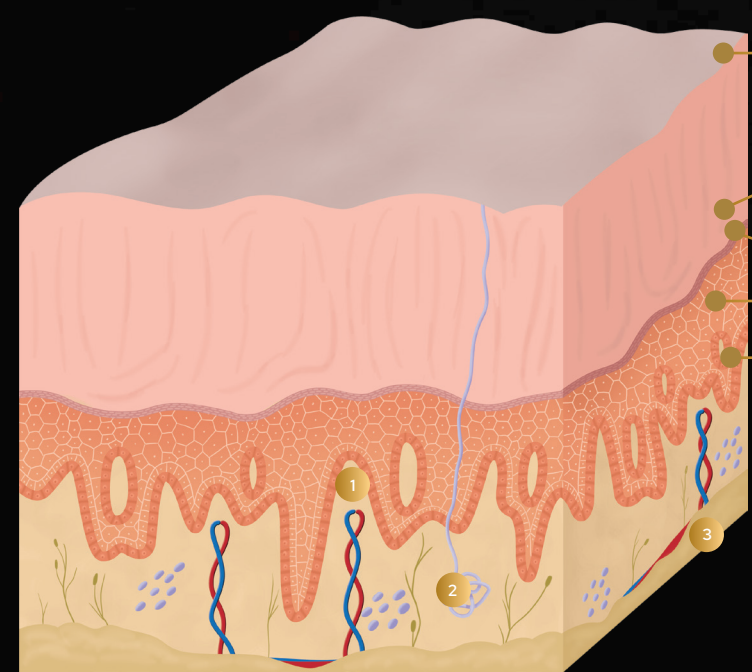
1. Apocrine gland
2. Sebaceous gland
3. Hair follicle
4. Cutaneous muscle
5. Adipose tissue

STRUCTURE OF HAIR FOLLICLE



1. Sebaceous gland
2. Follicle bulb
3. Dermal papilla
4. Arrector pili muscle
5. Venous sinuses

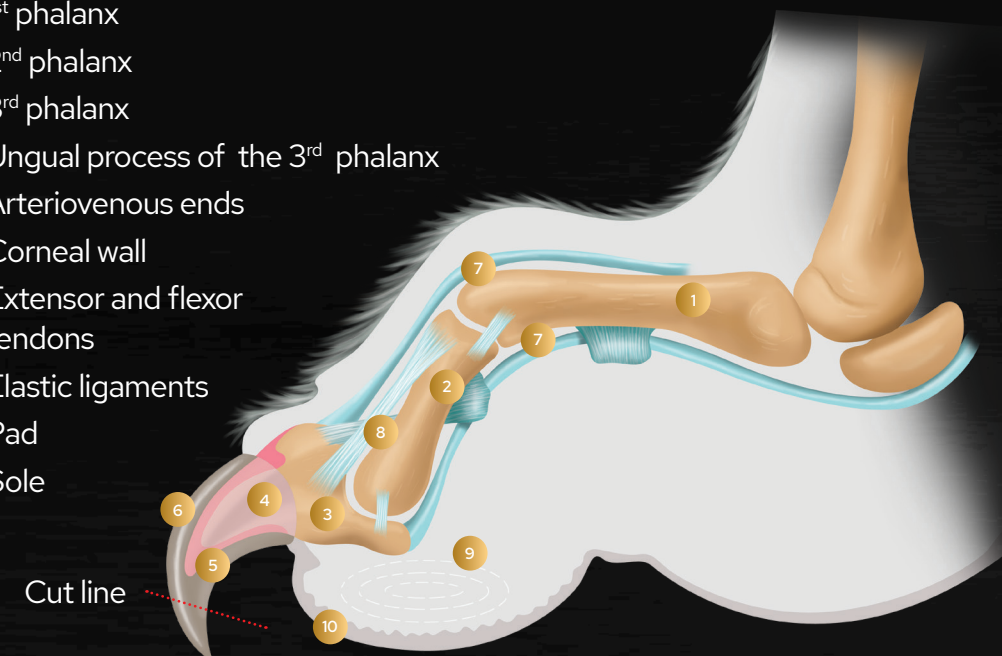
STRUCTURE OF FOOTPAD



- Horny layer
 - Clear layer
 - Granular layer
 - Spinous layer
 - Basal layer
1. Dermal papilla
 2. Sweat gland
 3. Adipose tissue

ANATOMY OF THE CLAW AND TRIMMING TECHNIQUE

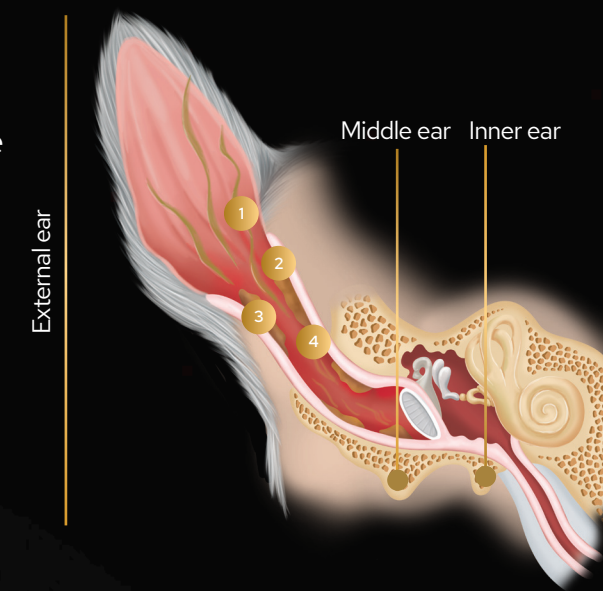
1. 1st phalanx
2. 2nd phalanx
3. 3rd phalanx
4. Ungual process of the 3rd phalanx
5. Arteriovenous ends
6. Corneal wall
7. Extensor and flexor tendons
8. Elastic ligaments
9. Pad
10. Sole



CLINICAL SIGNS OF SKIN CONDITIONS

OTITIS: INNER EAR CANAL INFLAMMATION

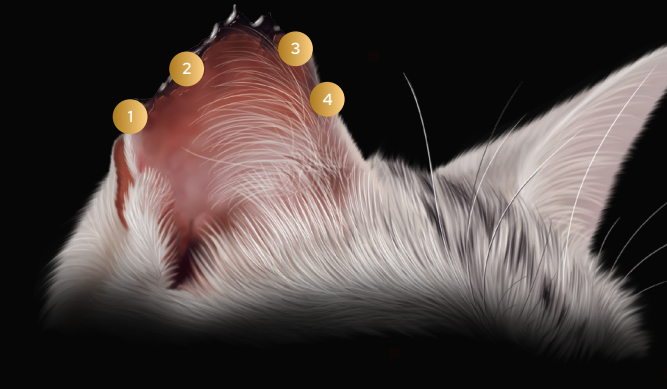
1. Apocrine gland
2. Sebaceous gland
3. Hair follicle
4. Cutaneous muscle
5. Adipose tissue



1. Excessive head shaking and scratching
2. Bad odour
3. Inflammation (thickening of ear canal)
4. Excess of exudate (secretions)
5. Erythema (redness)

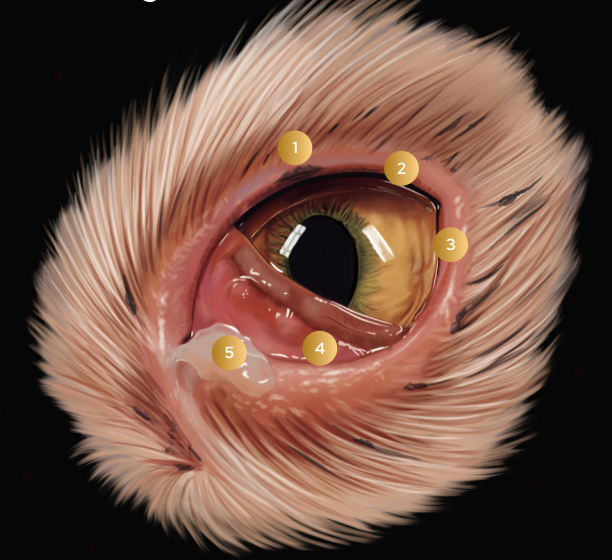ACTINIC KERATOSIS

1. Erythema (redness)
2. Flaking of skin
3. Crusts
4. Alopecia ((hair loss)

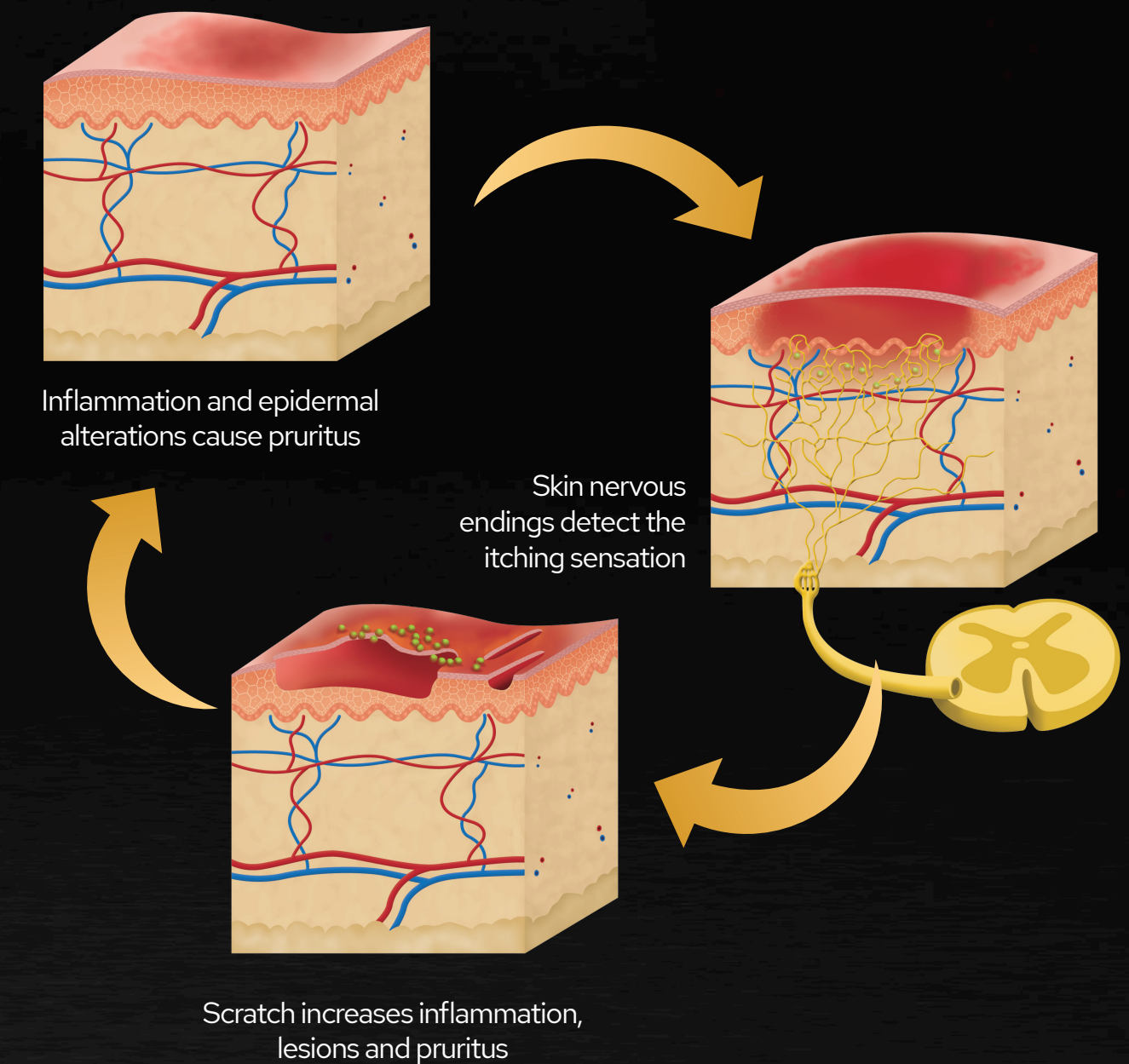


CONJUNCTIVITIS

1. Spasmodic blinking
2. Inflammation (swelling)
3. Erythema (redness)
4. Visible 3rd eyelid
5. Discharge



STAGES OF PRURITUS (ITCHING)



SKIN CONDITIONS IN CATS